Title:
Pseudo-Gaseous Inflammation Hypotheses Through Radiographic Analysis

Author:
André Silva Guzzon, MD

Abstract
I report a self-case radiographic observation of a subtle diminution in radiolucency of the tender Achilles tendon within a two-hour interval following administration of anti-inflammatory medications (IM dexamethasone 10 mg and oral ketoprofen 150 mg). Comparative analysis of both ankles before medication, as well as the left tendon pre- and post-treatment radiographs, shows a slight improvement in the Achilles region. This phenomenon suggests a potentially underestimated role of bubbly or pseudo-gaseous components in acute inflammatory processes.

Introduction / Background
Radiographic density is typically considered stable over short intervals, especially in the absence of trauma or structural interventions. However, subtle shifts in radiolucency may reveal dynamic inflammatory processes not widely acknowledged in radiologic or physiological literature. This report presents a rare opportunity to visualise such changes within a brief clinical window.
Recurrent radiographic images often show radiolucent areas at sites of acute inflammatory oedema, as illustrated in Figure 1 — an x-ray of a patient with suspected Achilles tendon rupture on physical examination — and in the classic “raised fat pad” sign, which presents a radiographic density much closer to atmospheric air than to fat, as noted in Figure 5.

Proposed Scientific Hypothesis
During inflammation, one or more blood components extravasated into the interstitium may chemically interact with extracellular structures, forming microscopic bubbles — analogous to an acid–base reaction. These microstructures could explain the observed radiolucency without requiring necrosis, infection, or external air.

Case Description
While working in an emergency department, I experienced mild discomfort in my left ankle and underwent radiographic examination (Images 2 and 3). Immediately after the exam, I received an IM dose of dexamethasone (10 mg) and an oral dose of ketoprofen (150 mg).
A follow-up radiograph of the left ankle was performed two hours later (Image 4).

Observational Findings

Careful comparison between the two radiographs reveals a subtle diminution in the radiolucent area surrounding the Achilles region. This suggests that inflammation produces low-density components that respond quickly to anti-inflammatory treatment — even within a short timeframe and via standard administration routes.

Discussion

The presence of radiolucent areas at sites of acute inflammatory oedema — and the rapid onset of visible changes in this case — raises compelling questions:
Could acute inflammation generate gaseous components when blood meets the interstitial environment, like an acid–base reaction?
Although limited to a single case (n = 1), this observation encourages further exploration into the dynamic interactions of acute inflammation. Additional studies are recommended to investigate the physiologic and pharmacologic influences on radiologic outcomes.

Images and Captions

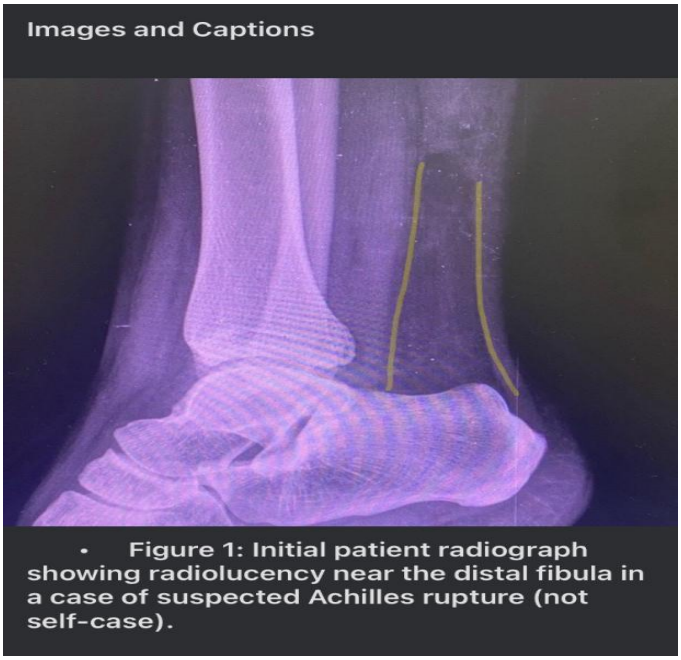

Figure 1: Initial patient radiograph showing radiolucency near the distal fibula in a case of suspected Achilles rupture (not self-case).

Figure 2: Right ankle (asymptomatic): No significant alterations. Serves as baseline reference.

Figure 3: Left ankle (pre-treatment): Mild pain (2/10) and discrete retrocalcaneal radiolucency compatible with inflammatory oedema.

Figure 4: Same ankle (2 hours post dexamethasone IM + ketoprofen PO, with full pain resolution): Subtle diminution in radiolucency, supporting its reactive and volatile inflammatory origin.

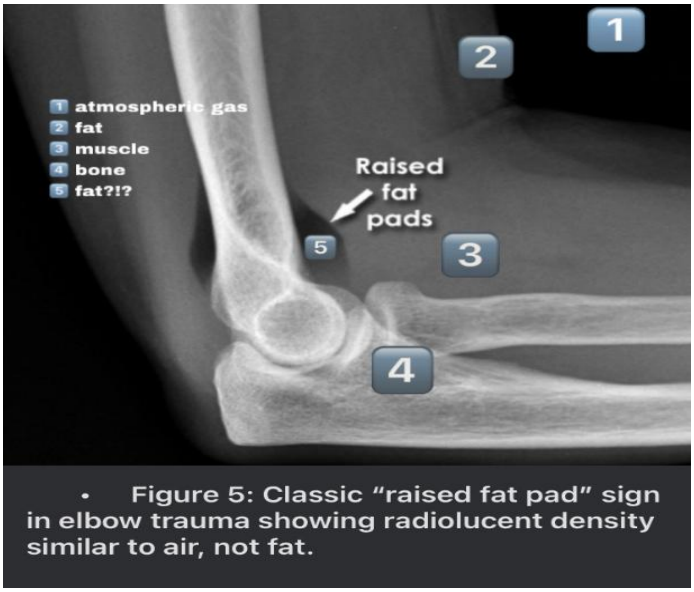

Figure 5: Classic "raised fat pad" sign in elbow trauma showing radiolucent density similar to air, not fat.

Logical Analysis: Acid–Base Conflict and Gas Formation in Extravascular Tissue Injury

Biochemical Foundations of Tissue Damage

Tissue injury, whether traumatic or inflammatory, involves the breakdown of cellular and vascular structures. Two well-documented facts are relevant:

- The intravascular compartment maintains a slightly alkaline pH, typically around 7.35–7.45;
- The intracellular compartment, once cells undergo lysis, exposes an acidic environment, with pH values often below 7.0;

In situations of trauma, inflammation, or cell death, these two chemically distinct environments come into direct contact — but outside the control of the usual homeostatic systems (e.g., lungs, kidneys, blood buffers).
This sets up a classic acid–base neutralization reaction, well described by general chemistry.

Neutralization: Expected Byproducts and Local Consequences.

When an acid reacts with a base, the products are:

Salt + Water + Gas
(typically, CO_2, especially in bicarbonate-buffered systems like blood and interstitial fluid)

Under physiological conditions, this reaction is tightly regulated within blood vessels. However, in extravascular tissues, this buffering is absent or insufficient.

Therefore, in areas of tissue damage:

- CO_2 generation should occur;
- Gas should accumulate locally, especially if perfusion is impaired;
- This gas is not rapidly cleared by the lungs or neutralized by renal mechanisms. Yet, in the classical model of edema, this phenomenon is largely ignored.

Contradiction with the Classical Edema Model

The prevailing theory states that inflammation leads to fluid leakage from blood vessels due to increased permeability. This leakage is assumed to be purely liquid, forming interstitial edema.

However:

• No mention is made of local gas generation, despite the acid–base interactions;
• No mechanistic explanation is offered for how the CO_2 formed in these reactions is instantly removed or neutralized;
• Radiological findings in certain cases — including subtle radiolucent patterns — suggest more than just fluid accumulation.

This presents a logical inconsistency in the accepted model.

Clinical Observations Align With Gas, Not Just Fluid
Radiographic evidence in trauma and inflammation sometimes reveals patterns that are:

• Inconsistent with fluid density alone;
• Variable with temperature or pressure, compatible with gas behavior;
• Disappear or shift with maneuvers that suggest compressible or thermolabile content.

These findings are often dismissed as artifact or incidental — yet they align closely with what would be expected from localized CO_2 formation.

Revisiting Inflammation Through the Lens of Acid–Base Logic
The inflammation cascade includes:

1. Cell lysis → release of acidic contents;
2. Vascular rupture → release of alkaline plasma;
3. Unbuffered environment → spontaneous acid–base reaction;
4. Byproduct → CO_2 gas, in addition to water and salt.

This process:
• Alters local pressure dynamics;
• Changes electromagnetic properties of the tissue;
• May impair diffusion and perfusion due to bubble-like structures, even if microscopic.

Conclusion: Gas Formation Is a Neglected but Logical Outcome
From a purely biochemical standpoint:

Wherever acid meets base, and buffering fails, gas is expected. If gas forms, it should accumulate — especially in damaged, poorly perfused tissue.
Therefore, while edema as fluid accumulation is valid, it may be incomplete. A full picture of inflammatory swelling must consider:
• Localized acid–base reactions;

• CO_2 generation and retention;

• Potential microbubble formation These factors may explain many subtleties of clinical imaging and patient response that the fluid-only model cannot.

References:

Empirical observations — there's a lot more at
https://www.tiktok.com/@5incere5cience?_t=ZM-90vZhFCG7Q4&_r=1